**PATIENT**

Cassie Fleischer

PRESENTING CLINICAL SIGNS

History: Decreased appetite, weight loss, diarrhea, and weak rear limbs. Was on Vetoryl.

SPECIES

Canine

Abnormal PE/Chem/CBC/UA Results: (08/19/2022) CBC: RBC 4.76, Hematocrit 33.5, Hemoglobin 12.2. CHEM: ALT 126, ALP 1518, GGT 36. ACTH Stimulation Test: Pre-ACTH 2.7 and Post-ACTH 5.4. (04/06/2022) ACTH Stimulation Test: Pre-ACTH 0.6 and Post-ACTH 1.6 (02/01/2022) CHEM: BUN 8, ALT 124, ALP 1460, GGT 23. LDDST: Pre-ACTH 0.5 and Post-ACTH 1.6. (01/31/2022) U/A (Freecatch): USG 1.009 and pH 6.5.

BREED

Labrador Retr.

ULTRASONOGRAPHIC EXAMINATION OF THE ABDOMEN**Urinary System****SEX**

Spayed Female

The **urinary bladder** is normal in thickness and the mucosal surface is smooth. The bladder lumen is moderately distended with anechoic urine. No masses, inflammatory changes or calculi are observed. The region of the trigone and the visible portion of the proximal urethra are normal.

AGE

13 years, 9 mos

The **left kidney** is normal size (6.70 cm in length); normal shape and architecture with smooth peripheral margins. There is a normal 1:3 cortex to medulla ratio with mild loss of corticomedullary distinction. There is no evidence of pyelectasia, nephroliths, infarcts or hydronephrosis. Renal vasculature is normal.

WEIGHT

58.2 lbs

The **right kidney** is normal size (7.26 cm in length); normal shape and architecture with smooth peripheral margins. There is a normal 1:3 cortex to medulla ratio with minimal loss of corticomedullary distinction. There is no evidence of pyelectasia, nephroliths, infarcts or hydronephrosis. Renal vasculature is normal.

INTERPRETED BY

Andrea Nicastro, DMV,
Diplomate DACVIM
(Small Animal
Internal Medicine)

Adrenal Glands

The **left adrenal gland** is enlarged (1.24 cm at cranial pole) (0.85 cm at caudal pole) (3.37 cm in length); with a slightly irregular shape. A 1.27 x 1.89 cm irregular, hyperechoic to slightly heterogenous nodule is observed the cranial aspect. Glandular echogenicity and detail at the caudal aspect are normal. The phrenicoabdominal vein and surrounding vasculature appear normal.

IMAGING PERFORMED BY

Potomac Mobile Vet US

The **right adrenal gland** is mildly enlarged (1.51 cm at cranial pole) (0.97 cm at caudal pole); with a slightly irregular shape. The parenchyma is subtly heterogenous with some loss of glandular detail. The phrenicoabdominal vein and surrounding vasculature are normal.

HOSPITAL NAME

Silver Spring AH

Spleen

The **spleen** is subjectively normal in size (1.67 cm in width at the level of the hilus) with slightly irregular peripheral contours. The parenchyma is subtly heterogenous with numerous, ill-defined hyperechoic nodules/areas. Splenic vasculature appears normal with no evidence of thrombosis.

REFERRING VET

Dr. Cathy Jarret

Liver

The **liver** is enlarged with irregular peripheral contours. On the left side, a >8.00 cm heterogenous mass is present. The lesion causes capsular expansion. In the remainder of the liver, the parenchyma is hypoechoic relative to the spleen. A few, ill-defined hypoechoic areas are seen. Hepatic vasculature and intrahepatic biliary tracts are of normal volume with no evidence of congestion.

INVOICE

11524

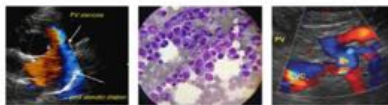
The **gall bladder** is of normal contours and contains some dependent echogenic debris. The wall is normal in thickness. No choleliths are observed. The cystic and common bile ducts are normal/not seen.

DATE

8.30.22

Gastrointestinal

The **gastric lumen** is not distended. The gastric wall is normal in thickness with a normal layering pattern. The small intestinal lumen is not dilated. The small intestinal wall thickness is normal with a

**PATIENT**

Cassie Fleischer

normal layering pattern and appropriate mural detail. Discreet masses are not identified. The colonic wall is normal. There is no evidence of an obstructive pattern.

SPECIES

Canine

Pancreas

A portion of the **pancreas** is obscured by the large hepatic mass. In the visualized portions, no obvious abnormalities are seen.

BREED

Labrador Retr.

Free Abdomen

There is no evidence of free fluid. The abdominal **lymph nodes** are normal/not visible.

ULTRASONOGRAPHIC FINDINGS**Primary Findings**

- Left hepatic mass. Neoplasia (i.e., adenoma, adenocarcinoma) is suspected, with a lower possibility of a benign process (i.e., excessive nodular hyperplasia).

SEX

Spayed Female

Secondary Findings

- The hyperechoic splenic lesions trend toward the benign (i.e., myelolipomas) with a low possibility of emerging neoplasia.
- Bilateral adrenomegaly, consistent with the previous diagnosis of pituitary-dependent hyperadrenocorticism. The left adrenal nodule could be consistent with benign nodular hyperplasia or an emerging tumor.
- Minor, age-related renal changes

AGE

13 years, 9 mos

WEIGHT

58.2 lbs

INTERPRETED BY

Andrea Nicastro, DMV,
Diplomate DACVIM
(Small Animal
Internal Medicine)

INTERPRETATION OF THE FINDINGS & FURTHER RECOMMENDATIONS

Three-view thoracic radiographs are recommended to assess for pulmonary metastases. If there is no evidence of pulmonary metastatic disease, consider hepatic mass removal with submission for histopathology. An abdominal CT scan may be useful in presurgical planning. Clotting times (PT/PTT) are recommended prior to surgery.

IMAGING PERFORMED BY

Potomac Mobile Vet US

HOSPITAL NAME

Silver Spring AH

REFERRING VET

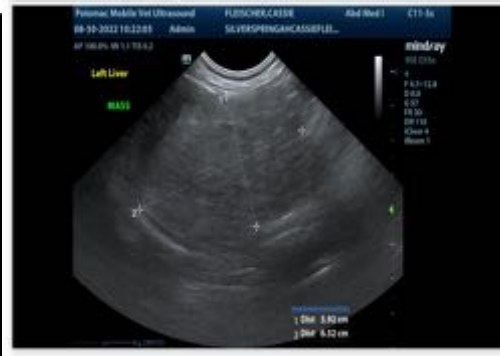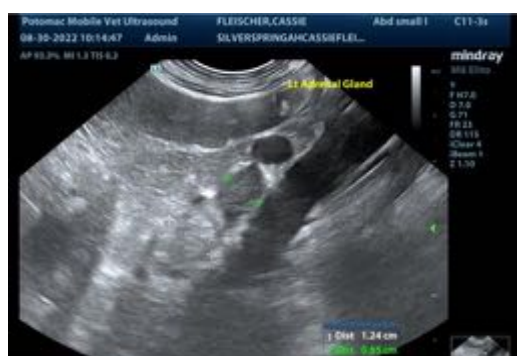Dr. Cathy Jarret

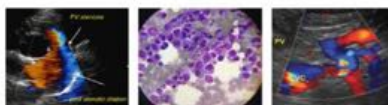
INVOICE

11524

DATE

8.30.22





PATIENT

Cassie Fleischer

SPECIES

Canine

BREED

Labrador Retr.

SEX

Spayed Female

AGE

13 years, 9 mos

WEIGHT

58.2 lbs

INTERPRETED BY

Andrea Nicastro, DMV,
Diplomate DACVIM
(Small Animal
Internal Medicine)

IMAGING PERFORMED BY

Potomac Mobile Vet US

HOSPITAL NAME

Silver Spring AH

REFERRING VET

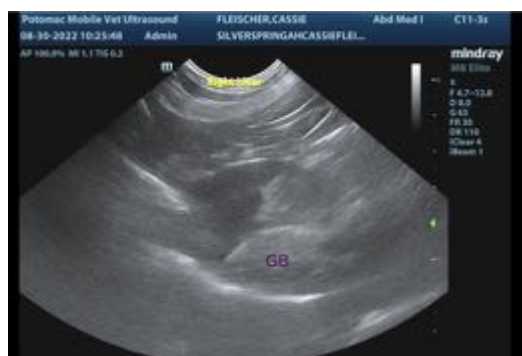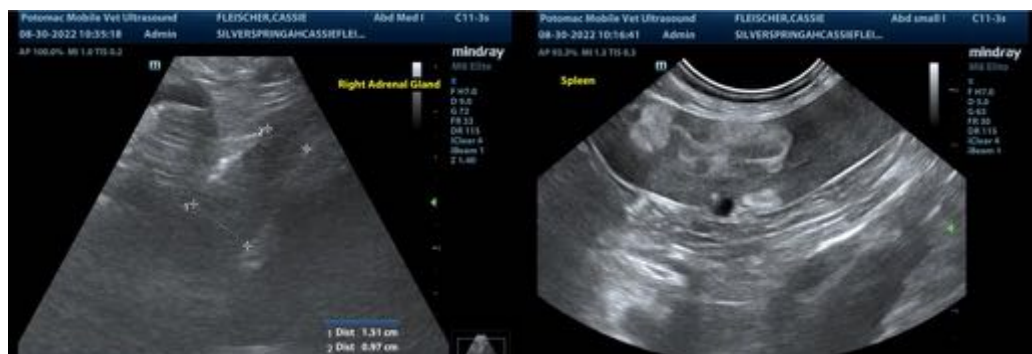Dr. Cathy Jarret

INVOICE

11524

DATE

8.30.22



The information and recommendations provided are based on the images presented by the referring veterinarian/sonographer. No evaluation can be communicated regarding pathology that was not visible in the image/video clips provided.

Thank you for this referral. If the clinical or image interpretation does not parallel your findings or if I can be of any further assistance, please contact me.

Andrea Nicastro, DVM, Diplomate DACVIM (Small Animal Internal Medicine)
info@SonoPath.com